TOXICOLOGICAL SCIENCES **84**, 394–407 (2005)
doi:10.1093/toxsci/kfi087
Advance Access publication January 19, 2005

Subchronic Exposure to Low Concentrations of Di-*n*-Butyl Phthalate Disrupts Spermatogenesis in *Xenopus laevis* Frogs

Shannon K. Lee, and D. N. Rao Veeramachaneni[1]

Animal Reproduction and Biotechnology Laboratory, Colorado State University, Fort Collins, Colorado 80523

Received December 6, 2004; accepted January 10, 2005

Due to its widespread use and production, di-*n*-butyl phthalate (DBP) has become an environmental contaminant. It has been detected in a variety of environmental strata worldwide, including air, water, and soil. Also, monobutyl phthalate, the major metabolite of DBP, has been detected in a variety of human matrices. As a proven endocrine disruptive compound, DBP may contribute to global amphibian declines at much lower concentrations than tested thus far. We evaluated the effects of low concentrations of DBP on spermatogenesis in *Xenopus laevis,* the African clawed frog. *Xenopus* tadpoles were exposed to 0, 0.1, 0.5, 1.0, 5.0, or 10.0 ppm DBP, beginning at sexual differentiation (Nieuwkoop and Faber stage 52; 3 weeks of age) and continuing until 100% of controls metamorphosed (stage 66; 8 weeks of age). Upon necropsy at 33 weeks, 4–6% of DBP-treated frogs had only one testis, and 2–4% had retained oviducts. In all DBP treatment groups, seminiferous tubule diameter and the average number of germ cell nests per tubule were lower, and the number of tubules with no germ cells was significantly higher ($p < 0.05$). The percent of secondary spermatogonial cell nests significantly decreased ($p < 0.05$) in 1.0, 5.0, and 10.0 ppm groups. Several lesions occurred in DBP-exposed testes including denudation of germ cells, vacuolization of Sertoli cell cytoplasm, thickening of lamina propria of seminiferous tubules, and focal lymphocytic infiltration. Entire sections of testes containing almost exclusively mature spermatozoa were found in 1.0, 5.0, and 10.0 ppm DBP-exposed testes, indicating impairment of spermiation. Testicular hypoplasia and seminiferous tubular dysgenesis were also evident in DBP-treated frogs. Thus, subchronic exposure to low concentrations of DBP impairs spermatogenesis in *Xenopus laevis* frogs.

Key Words: **amphibian declines; sexual differentiation; testicular dysgenesis; testicular hypoplasia; impaired spermiation; Sertoli cell lesions.**

Di-*n*-butyl phthalate (DBP) belongs to a group of compounds known as phthalate esters—diesters of 1,2-dicarboxylic acid. DBP is a specialty plasticizer and is used in a multitude of consumer products including food-packaging materials and cosmetics (Brandt, 1985; Petersen *et al.*, 2000). DBP leaches from these products and, thus, has become a common contaminant; it has been identified in environmental strata, including air, water, and soil (A.T.S.D.R., 2001 [drinking water: 0.1–5.0 ppb]; Otake *et al.*, 2004 [indoor air: 0.01–6.18 μg/m^3 (ppm)]; Peterson and Freeman, 1982 [soil: 18–89 ppb]). Human exposure to DBP has been confirmed by several studies: DBP (0.11–14.76 μg/m^3 (ppm)) was present in 100% of personal air samples from women in New York, NY, and Krakow, Poland (Adibi *et al.*, 2003); DBP was present in 68% of serum samples from Puerto Rican girls experiencing thelarche (premature puberty); the concentrations of several phthalate esters, including DBP, in seminal plasma were significantly higher ($p < 0.05$) in infertile men (2.03 μg/ml (ppm)) compared to controls (0.06 μg/ml (ppm)) (Rozati *et al.*, 2002); and monobutyl phthalate, a metabolite of DBP, was present at particularly high concentrations (312–2,763 μg/g creatinine (ppb)) in random urine samples from women of reproductive age (20–40 years) (Blount *et al.*, 2000). Considering that DBP is metabolized and eliminated from the body within 48 h of exposure in mammals (Kluwe, 1982), and that monobutyl phthalate was identified in random samples of various matrices, it is very likely that exposure to DBP is continuous in several populations of animals and humans and that DBP is indeed an ubiquitous environmental contaminant.

DBP is a known endocrine disruptor. It is a developmental toxicant that has pronounced adverse effects on the male reproductive tract. DBP causes a variety of terata, and these vary depending on the window of exposure. For instance, pregnant rats given DBP by gastric intubation at a dose of 750, 1000, or 1500 mg/kg/day on gestation days 7–9, 10–12, or 13–15 resulted in 100% post-implantation loss in the 1500 mg/kg/day dose group, an increase in the number of skeletal malformations (deformity of vertebral column) when treated with 750 and 1000 mg DBP/kg/day on gestation days 7–9, and a dose-dependent increase in the number of external and internal malformations such as cleft palate and fusion of the sternebrae when exposed on gestation days 13–15 (Ema *et al.*, 1994). Likewise, exposure to DBP (400–500 mg/kg/day) during reproductive development in rodent and nonrodent species results in a variety of malformations of the male reproductive tract, including aplastic or absent epididymides

[1] To whom correspondence should be addressed at Animal Reproduction and Biotechnology Laboratory, Colorado State University, Fort Collins, CO 80523–1683. Fax: (970) 491-3557. E-mail: rao@colostate.edu.

Toxicological Sciences vol. 84 no. 2 © The Author 2005. Published by Oxford University Press on behalf of the Society of Toxicology. All rights reserved.
For Permissions, please email: journals.permissions@oupjournals.org

Downloaded from http://toxsci.oxfordjournals.org/ at University of North Texas on January 21, 2017

and accessory sex glands, reduced anogenital distance, testicular atrophy, a decline in number of ejaculated sperm, an increase in number of abnormal sperm, cryptorchidism, and hypospadias (Gray *et al.*, 1999, 2001; Higuchi *et al.*, 2003; Mylchreest *et al.*, 1999, 2000, 2002). DBP also induces histopathological changes within seminiferous epithelium in rats and rabbits, including widespread germ cell loss, vacuolization of Sertoli cell cytoplasm, Leydig cell hyperplasia, presence of giant cells, dysgenetic seminiferous tubules, and atypical germ cells resembling carcinoma *in situ* cells (Fisher *et al.*, 2003; Higuchi *et al.*, 2003).

While many studies have focused on the deleterious effects of DBP at high doses in mammals, few studies have investigated the effects of environmentally relevant concentrations of DBP in aquatic vertebrates. It is now generally accepted that many species of amphibians are on the decline, and some face extinction (Houlahan *et al.*, 2000; Stuart *et al.*, 2004). A number of factors including habitat loss, increased susceptibility to disease and parasites, climate changes, acid precipitation, introduced invasive predators, increased exposure to ultraviolet radiation, and environmental contaminants including endocrine disruptive compounds (EDCs) potentially contribute to these trends (reviewed by Blaustein *et al.*, 2002). Several studies indicate that EDCs cause reproductive abnormalities and limb malformations in amphibians (Burkhart *et al.*, 1998; Hayes *et al.*, 2003; Kloas *et al.*, 1999; Levy *et al.*, 2004; Ohtani *et al.*, 2000). According to the *12th Annual National Listing of Fish Advisories* released by the EPA in 2004, 35% of total lake acres and 24% of river miles in the nation are contaminated with one or more of 40 different pollutants including mercury, PCBs, DDT, chlordane, and polyvinyl chloride (contains phthalates). However, tissue samples from fish and shellfish were not collected from all bodies of water within a state, so it is plausible that even more are contaminated (U.S. EPA, 2004). Thus, aquatic population trends from these and other sites may serve as ecological harbingers for the future of more complex organisms.

Loss of reproductive competence as a result of exposure to EDCs, such as DBP, is a fundamental aspect to be considered in preserving environmental health. Impairment of the spermatogenic process in a species could significantly reduce the number of offspring and may render the species unsustainable. In light of this, and given recent declines in amphibian populations, this study was undertaken to evaluate the effects of low, environmentally relevant concentrations of DBP on spermatogenesis in *Xenopus laevis* frogs.

MATERIALS AND METHODS

Experimental design. *Xenopus laevis* tadpoles were exposed to DBP beginning at sexual differentiation (3 weeks of age; stage 52; staging based on Nieuwkoop and Faber, 1967) and continued through metamorphosis (8 weeks of age; stage 66; metamorphosis is complete). All juvenile frogs were thereafter maintained in a dilute salt solution only (detailed below) until 33 weeks (when mature spermatozoa are present in seminiferous tubules), at which time all animals were euthanized, and tissues were evaluated.

Adult husbandry and embryo collection. Eight pairs of adult, proven-breeder, male and female *Xenopus laevis* frogs were procured from Nasco (Fort Atkinson, WI). Breeders were kept on a 12:12 h light:dark cycle, in polypropylene tubs (two frogs of the same gender per tub) containing 10 l of a 10 mM NaCl (Morton's noniodized pickling salt) solution. The solution was changed daily, and 10–12 pellets of Aquamax Grower 600 (PMI Nutrition International, Inc., Brentwood, MO) were placed in each tub. The temperature in the room ranged from 20 to 24°C.

To induce amplexus and oviposition, eight males and eight females were primed with an injection of 250 IU of human chorionic gonadotropin into the dorsal lymph sac, followed 2 h later by a second injection of 400 IU, in the case of the males, or 800 IU, in the case of the females. After the final injection, one male and one female were placed together in a 2.5-gallon glass tank fitted with a false bottom, containing 5 l of salt solution (625 mg NaCl, 96 mg $NaHCO_3$, 30 mg KCl, 15 mg $CaCl_2$, 60 mg $CaSO_4{\cdot}2H_2O$, and 75 mg $MgSO_4$ per liter of deionized water; pH = 7.6–7.9). This solution is used as a culture medium in conducting the Frog Embryo Teratogenesis Assay-Xenopus (FETAX; A.S.T.M., 1998) and hereinafter is referred to as FETAX solution. Each tank was covered with a box to provide darkness throughout the day, and the frogs were allowed to breed overnight.

The following day, the clutches of embryos from each breeding pair were macroscopically evaluated, and only those of the highest quality were saved for the experiment (i.e., only those clutches of embryos contained in clean water, not connected in strings, and not associated with several necrotic embryos). Acceptable clutches of embryos were washed thoroughly with FETAX solution and were handled individually throughout the sorting process. Embryos were sorted and cultured following standard guidelines for FETAX (A.S.T.M., 1998). Briefly, embryos were exposed to 2% w/v L-cysteine (pH = 8.1) (Sigma-Aldrich CAS no. 52–90–4) for approximately 2 min to remove the jelly coat. Embryos were then rinsed thoroughly with FETAX solution and placed in large glass Pyrex dishes containing FETAX solution to ensure minimal egg-to-egg contact while sorting. Using a dissecting microscope clean, round, normally cleaving embryos of stages 8 (mid-blastula) to 11 (early gastrula) were sorted and cultured. The following exceptions to ASTM guidelines were made for culture conditions: (a) 100 mm Pyrex glass Petri dishes were used instead of the stipulated 55 mm polystyrene dishes to avoid possible leaching of contaminants into the test system from plastic; (b) two dishes per concentration with 50 embryos/dish having 20 ml of medium instead of the recommended two dishes each with 25 embryos in 10 ml of medium (Lee *et al.*, in press; Weber *et al.*, 2004).

Tadpole husbandry and dosing. *Xenopus* embryos generated from three breeding pairs were used. Embryos from the three clutches were maintained separately for the duration of the experiment. All embryos were raised in FETAX solution, in incubators, for the first 96 h of life. From 96 h to 21 days of life tadpoles were maintained in 20-gallon glass aquaria containing FETAX solution at a density of 2.5 tadpoles/l; aquaria and media were changed every Monday, Wednesday, and Friday.

Beginning at the onset of sexual differentiation (stage 52; 3 weeks of age), tadpoles were randomly divided into seven treatment groups: FETAX solution only (control; $n = 311$); 0.01% dimethyl sulfoxide (DMSO-solvent control; $n = 313$); 0.1 ($n = 273$), 0.5 ($n = 389$), 1.0 ($n = 428$), 5.0 ($n = 664$), or 10.0 ppm ($n = 395$) DBP dissolved in 0.01% DMSO. More tadpoles were allocated to the 5.0 ppm group to ensure availability of sufficient sample size. Based on our FETAX experiments (Higuchi *et al.*, 2000; Lee *et al.*, in press) that showed high rates of embryonic mortality at 10 ppm, we speculated that the 5.0 ppm DBP would be optimal for a high concentration that does not compromise survival of tadpoles. Large sample size is an important consideration when testing low concentrations of a chemical such as DBP that produces highly variable results within a population. Animals continued to be raised at a density of 2.5 tadpoles/l, and dosing continued until 100% of the controls had completed metamorphosis at 8 weeks of age.

Downloaded from http://toxsci.oxfordjournals.org/ at University of North Texas on January 21, 2017

Stock solutions were made in 100-ml amber glass bottles every week. Using a Hamilton syringe, DBP (Sigma-Aldrich; CAS no. 84–74–2; lot no. 12607AA; 99.8% pure) was added directly to DMSO (Fisher; CAS no. 67–68–5; 99.9% purity). At each renewal, dosing solutions were added using glass pipettes, and the contents of each tank were manually stirred using an acetone-washed glass rod. After allowing the chemical to disperse for approximately 10 min, the animals were transferred. After every change all tanks were thoroughly hand-scrubbed and rinsed with hot tap water to avoid loss of chemical to the test system by adsorption to the glassware, which could overstate the toxicity value (Adams *et al.*, 1995), and then washed a second time in a 636 Steris Washer at 180°F. Animals were kept on a 12:12 h light:dark cycle. The temperature of the room throughout the experiment ranged from 21 to 24°C.

Beginning at 96 h, tadpoles were fed daily a slurry of ground trout chow (Xenopus One, Dexter, MI) prepared in deionized water. The concentration and volume of the slurry added each day was determined by the rate of clearance of the slurry once added to the tank the previous day. Thus, as the tadpoles grew, the concentration of the slurry increased so as to provide feed *ad libitum*. The adequacy of this method was evidenced by the normal rate of development of the tadpoles in the control tanks. Once the tadpoles began to develop into stage 64–66 juvenile frogs, the feeding regimen consisted of a concentrated slurry and 1 tablespoon of Aquamax Grower 400 pellets per 20 liters.

Upon cessation of dosing at 8 weeks of age, animals in all treatment groups were maintained in FETAX solution alone at a density of 1.5 frogs/l, and were fed Aquamax Grower 400 (2 tablespoons/10 l) three times per week.

Tissue sampling and processing. At 33 weeks of age, frogs were anesthetized using 3.0% w/v MS-222 (CAS no. 886–86–2; Sigma-Aldrich, Milwaukee, WI), weighed, and euthanized by severing the spinal cord. All females were culled. To avoid sampling errors due to a potentially large variation in body size within a tank, only the male frogs within ± 2 SD of the mean body weight for that particular tank were included for tissue collection. Blood plasma was collected from control, solvent control, 0.1, 1.0, and 10.0 ppm DBP-treated males. The brachial plexus and the right vena cava were punctured, and blood samples were withdrawn using capillary tubes and emptied into 2-ml glass vials containing EDTA. Plasma was separated by centrifugation for 10 min at 5000 rpm and stored at −20°C until assayed for testosterone.

Testes and kidneys (hereinafter will be referred to as testis-kidney complexes) were removed as a unit (to keep the testicular excurrent ducts intact), weighed, and placed in 4% glutaraldehyde in 0.1 M cacodylate buffer (pH = 7.4) containing 5% sucrose. Larynges were also removed, weighed, and placed in Bouin's solution.

Forty-eight h after fixation in Bouin's solution, testis-kidney complexes were rinsed in water and stored in 70% ethanol, dehydrated in a series of graded alcohols, and embedded in paraffin wax. Twenty to sixty 6-μm-thick sections, parallel to the longitudinal axis of the testis, were cut using a Leica RM 2135 microtome, collected serially on glass slides, and stained with hematoxylin and eosin (H&E).

Testis-kidney complexes stored in the glutaraldehyde mixture were rinsed in 0.1 M cacodylate buffer (pH = 7.4) 24 h after fixation, post-fixed for 90 min in 1.0% osmium tetroxide in 0.1 M cacodylate buffer, rinsed in buffer, dehydrated through graded alcohols, and embedded in Poly/Bed 812 (Polysciences Inc., Warrington, PA). One-micron-thick sections were cut and stained with toluidine blue or a differential stain consisting of methylene blue, azure II, and safranin O (Laczko and Levai, 1975), and evaluated using a Nikon Microphot FXA light microscope. Sixty- to 80-nm-thick sections were cut, stained with uranyl acetate and lead citrate, and examined using a JOEL-1200EX transmission electron microscope.

Gross abnormalities and testicular morphometry. At necropsy, visceral and reproductive organs were examined, and any gross abnormalities observed were recorded. Unique abnormalities were photographed at high resolution using a Nikon Coolpix 990 digital camera. Abnormalities within the reproductive tract included missing testis and retained oviducts.

Testicular length and width were measured using the slide containing the largest (as determined by smaller sections on either side of the sequence of serial sections) 6-μm-thick section; the same section was used for histological evaluations. Using a Nikon-Eclipse E800 microscope interfaced with a computerized Image Pro (version 4.0) imaging system, images of entire sections were captured, and length and width of each testis were measured.

Using an Olympus-BH2 microscope, diameters of up to 50 (25 from each testis) randomly selected, essentially round (<1.5× width), seminiferous tubules from each animal were measured at their major axes.

Quantitative evaluation of spermatogenesis and testicular histopathology. Seminiferous epithelium and interstitium were evaluated using the largest 6-μm-thick section stained with H&E (light microscopy) and 60–80-nm-thick sections stained with uranyl acetate and lead citrate (transmission electron microscopy). Up to 100 (50 from each testis) randomly selected, essentially round seminiferous tubules from each animal were evaluated and histological lesions recorded. The entire area of each testis was used in the evaluation. Testis-kidney sections from each animal were evaluated at a final magnification of 200×. All germ cell nests within each tubule were classified into one of five different categories based on the dominant germ cell type present within that nest: secondary spermatogonial, primary spermatocytic, secondary spermatocytic, spermatidal, or no nests (Fig. 1). Criteria for identification of germ cell type were based on histological features described by Kalt *et al.* (1976). As in mammals, two morphologically distinct spermatogonial cells exist in amphibians, primary and secondary; these are equivalent to type A and type B spermatogonia in mammals (Lofts, 1968). Primary spermatogonial nests are small and are of variable size. Unlike primary spermatogonial nests, secondary spermatogonial nests are larger and more uniform in size facilitating enumeration. Therefore, only secondary spermatogonial nests were categorized. In tubules that contained no germ cell nests only Sertoli cells were remaining, and therefore these tubules were referred to as Sertoli-cell-only (SCO) tubules.

Any testicular lesions were further characterized at the ultrastructural level using tissues fixed in glutaraldehyde (two blocks of tissue each from controls, 5.0 ppm, and 10.0 ppm DBP). Only qualitative evaluation of lesions was conducted because quantitative evaluation using electron microscopy for these purposes is impractical.

Testosterone. Testosterone concentration in plasma samples was measured using a commercially available kit (Diagnostic Products Corporation, Los Angeles, CA), which has been used for the serum of *Xenopus laevis* (Kang *et al.*, 1995). Data from the manufacturer indicate that the assay is specific for testosterone (3.3% cross-reactivity with DHT, 0.02% cross-reactivity with estradiol, and <2% for other steroids present in serum). According to the manufacturer, the use of this kit for assaying EDTA plasma samples results in values that are about 10% lower. The sensitivity of this assay was 0.04 ng/ml. Accuracy of this assay for plasma was determined by spiking a sample of plasma, pooled from four adult female frogs, with 0.8, 3.2, and 12.8 ng/ml testosterone and plotting the amount of ligand added versus the amount measured. The slope of the line was 0.803, and the correlation coefficient was 0.999. Each plasma sample was analyzed in duplicate. Samples with coefficients of variation greater than 20% were not included in the statistical analyses. The intra- and inter-assay coefficients of variation were determined from two quality control samples of female plasma containing added concentrations representing three points in the middle of the standard curve. The intra- and inter-assay ($n = 3$) coefficients of variation were 5.16% and 5.70%, respectively.

Statistical analyses. Since no significant differences existed between clutches, the data from all clutches were pooled for final statistical analyses. Data were analyzed using analysis of variance (ANOVA) using StatView (version 5.0, SAS Institute Inc., Cary, NC). Means were compared using the Tukey-Kramer post hoc test at an alpha of 5%. Percentage values were transformed to minimize any inequalities in variance by using arcsine of the square root of the variable/100.

Downloaded from http://toxsci.oxfordjournals.org/ at University of North Texas on January 21, 2017

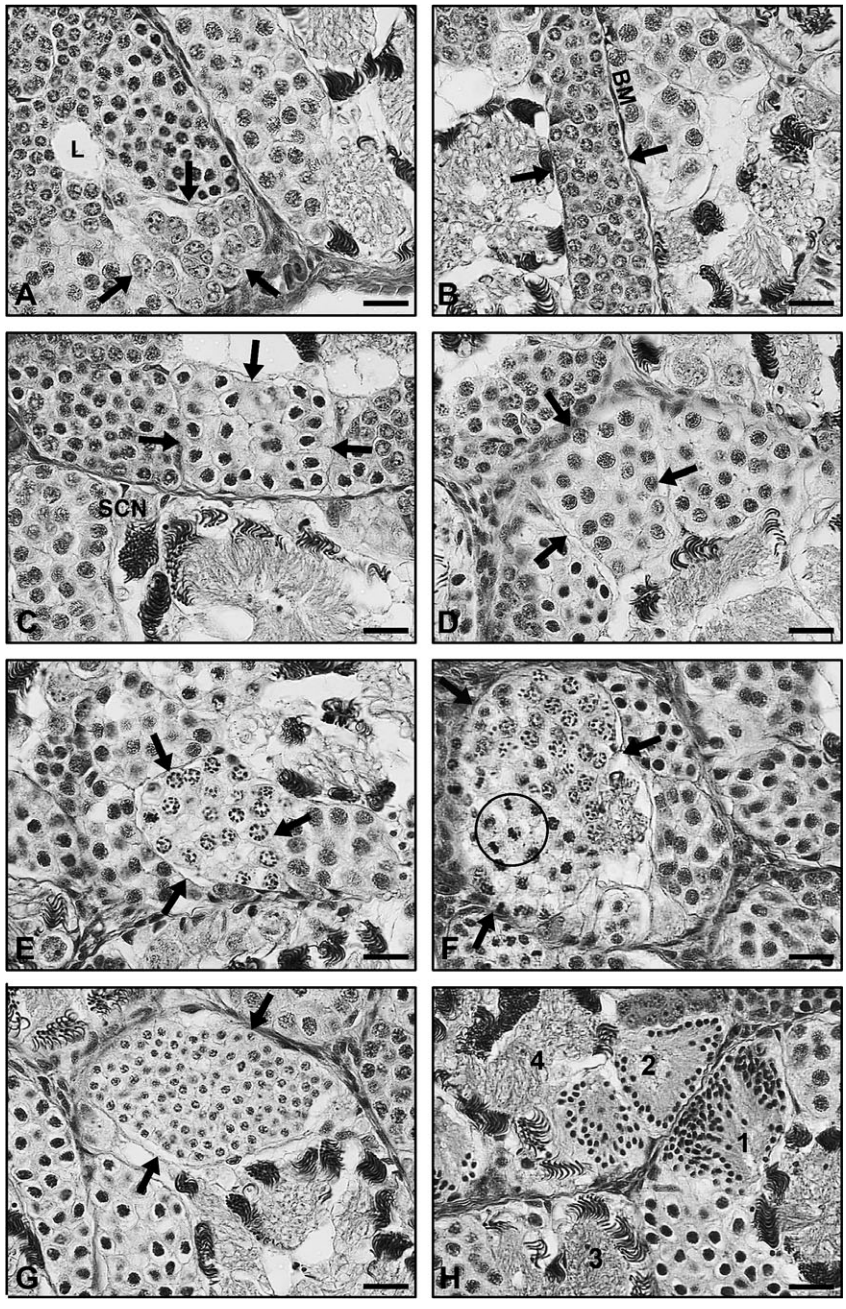

FIG. 1. Stages of spermatogenesis in *Xenopus laevis.* (A) Secondary spermatogonial nests. (B) Leptotene primary spermatocytic nest. (C) Zygotene primary spermatocytic nest. (D) Pachytene primary spermatocytic nest. (E) Diplotene primary spermatocytic nest. (F) Secondary spermatocytic nest. (G) Round spermatidal nest. (H) Numbers 1–4 show the progression of spermiogenesis from elongating spermatids to luminal spermatozoa. BM = basement membrane, L = lumen of tubule, SCN = Sertoli cell nucleus. Bar = 20 μm.

RESULTS

Mortality and Gross Abnormalities

Cumulative mortalities from 21 days to 33 weeks of age for control, solvent control, 0.1, 0.5, 1.0, 5.0, and 10.0 ppm DBP were 3, 3, 5, 4, 5, 9, and 16%, respectively.

In all DBP treatment groups some frogs had only one testis; the incidence of missing testes for control, solvent control, 0.1, 0.5, 1.0, 5.0, and 10.0 ppm DBP groups were 0, 0, 4, 4, 6, 4, and 4%, respectively. Well-developed oviducts were present in 0.1, 0.5, 1.0, and 5.0 ppm DBP-treated males at the following frequencies: 2, 2, 2, and 4%, respectively (Fig. 2). None of the males in control and solvent control groups had well-developed oviducts. The numbers of malformed males with missing testis or presence of oviducts were not statistically significant ($p > 0.05$).

Downloaded from http://toxsci.oxfordjournals.org/ at University of North Texas on January 21, 2017

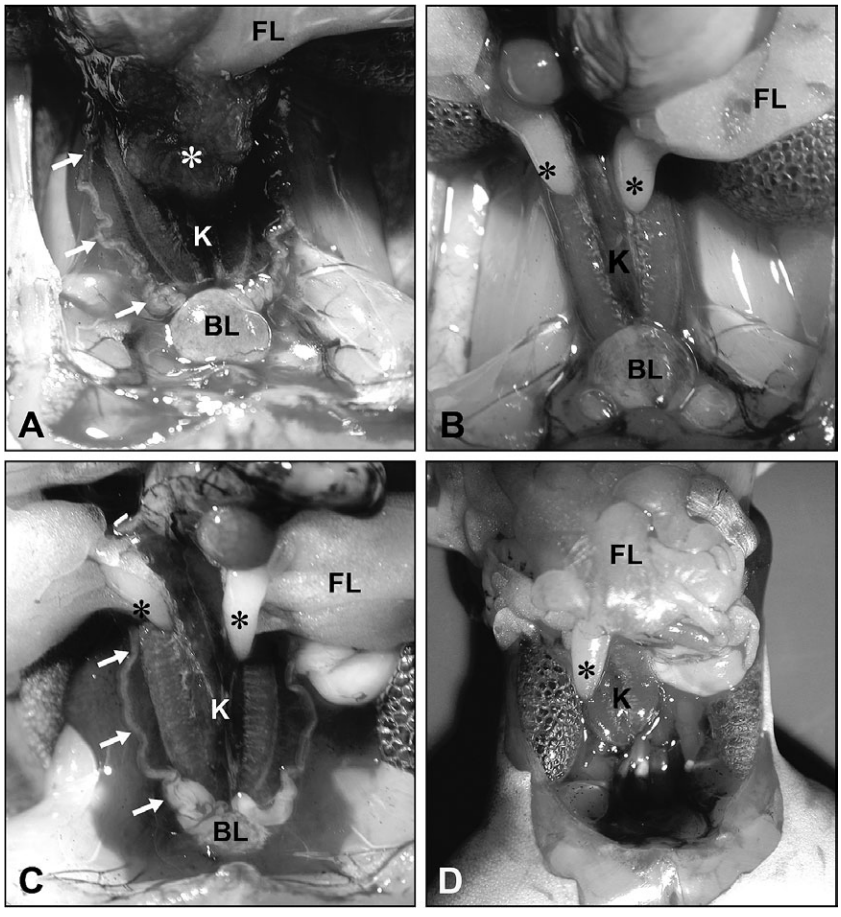

FIG. 2. Gross lesions of the male reproductive tract at 33 weeks of age. (A) Normal female with convoluted oviducts (arrows) and developing ovary lobules (asterisk) in which oocytes are visible. (B) Normal male with developed testes (asterisks) and no remnants of the Müllerian ducts. (C) Feminized 0.1 ppm DBP-treated male with intact oviducts (arrows) and developed testes (asterisks). (D) 5.0 ppm DBP-treated male with only one testis (asterisk); attachments cut, kidneys are retracted cranially. B = bladder, K = kidney, FL = fat lobules.

Weights and Testicular Morphometry

At 33 weeks mean testis-kidney and whole body weights were significantly lower in all DBP treatment groups ($p < 0.05$). However, mean testis-kidney weight normalized to body weight was significantly different from control only at the 10.0 ppm DBP treatment level ($p < 0.05$). Mean laryngeal weight was significantly reduced at 1.0 ppm DBP and above ($p < 0.05$). However, this statistical significance was lost when laryngeal weights were normalized to body weight.

Frequently, testes within an animal were found to be asymmetrical. However, disproportionate testes were not always an indication of an increased incidence of lesions; overall, only three small testes had an increased incidence of histological lesions. The average testis length was significantly shorter in all DBP treatment groups ($p < 0.05$) compared to control and solvent control groups (Table 1). However, the average testis width was significantly less only in 5.0 and 10.0 ppm DBP treatment groups ($p < 0.05$). Additionally, the average tubule diameter was significantly reduced in all DBP treatment groups ($p < 0.01$).

Quantitative Evaluation of Spermatogenesis

Histological evaluation of testes indicated impaired spermatogenesis. The average number of cell nests per tubule cross section decreased in all DBP-treated frogs ($p < 0.05$) (Table 2). Also, although not quantified, the number of germ cells constituting a cell nest in any stage of spermatogenesis was noticeably decreased in all DBP treatment groups. This apparent decrease in cell number per nest led to a conspicuous regression of the testis, which was evident starting at 0.1 ppm DBP (Fig. 3).

The percent of secondary spermatogonial nests significantly decreased ($p < 0.05$) in 1.0, 5.0, and 10.0 ppm DBP treatment groups. Except for a significant increase ($p < 0.05$) in the percent of primary spermatocytic nests in the 5.0 ppm DBP group, no changes were observed in any of the treatment

Downloaded from http://toxsci.oxfordjournals.org/ at University of North Texas on January 21, 2017

TABLE 1
Effects of DBP Exposure During Sexual Differentiation: Organ Weights and Morphometry of the Testis

Treatment	N[a]	Body Weight[a] (g)	Testis-Kidney Weight[a] (mg)	Testis-Kidney/Body Weight[a] (mg)	N[b]	Larynx Weight[b] (mg)	Larynx/Body Weight[b] (mg)	Testis Length[b] (mm)	Testis Width[b] (mm)	Seminiferous Tubule Diameter[b] (μm)
FETAX Solution Control	44	19.8 ± 1.08	121.4 ± 7.41	6.1 ± 0.15	27	378.7 ± 26.42	19.6 ± 0.50	4.3 ± 0.19	1.6 ± 0.07	147.6 ± 1.14
0.01% DMSO Solvent Control	40	19.8 ± 1.07	123.1 ± 7.46	6.1 ± 0.12	26	346.3 ± 24.01	19.0 ± 0.52	4.0 ± 0.16	1.6 ± 0.06	146.9 ± 1.14
0.1 ppm DBP	45	15.5 ± 0.88*	89.4 ± 6.60*	5.1 ± 0.15	28	284.2 ± 24.22	19.7 ± 1.76	3.5 ± 0.17*	1.5 ± 0.07	114.6 ± 1.14*
0.5 ppm DBP	48	13.5 ± 0.48*	87.1 ± 4.10*	6.4 ± 0.13	27	259.5 ± 22.06	18.0 ± 0.77	3.5 ± 0.19*	1.4 ± 0.06	108.5 ± 1.10*
1.0 ppm DBP	48	13.0 ± 0.67*	74.2 ± 6.04*	5.5 ± 0.17	28	223.9 ± 19.15*	18.2 ± 0.79	3.3 ± 0.17*	1.3 ± 0.07	94.9 ± 1.10*
5.0 ppm DBP	48	11.5 ± 0.43*	69.0 ± 2.83*	6.1 ± 0.18	29	215.7 ± 13.57*	19.0 ± 0.81	3.2 ± 0.16*	1.2 ± 0.05*	87.4 ± 0.92*
10.0 ppm DBP	46	11.6 ± 0.49*	66.7 ± 5.12*	5.2 ± 0.23*	29	208.2 ± 19.28*	16.4 ± 0.59	2.9 ± 0.17*	1.3 ± 0.08*	82.8 ± 0.96*

Mean ± SE.
[a]Represents all animals whose tissues were processed for light and electron microscopy.
[b]Represents only animals whose tissues were processed for light microscopy.
*Significantly different ($p < 0.05$) from controls and solvent controls using ANOVA and Tukey/Kramer post-hoc test.

groups in the distribution of spermatocytic or spermatidal nests. The percent of tubules that contained no germ cell nests significantly increased in all DBP treatment groups ($p < 0.01$) (Table 2).

Testicular Histopathology

Histopathological changes were observed in testes from frogs treated with 0.1 ppm DBP and above. Dying germ cells were often encountered in nests of DBP-treated frogs. Interestingly, widespread round spermatid death was frequently observed (Figs. 4A and 4B), particularly in tubules that had recently spermiated or retained elongated spermatozoa. Foci of dying early leptotene primary spermatocytes were also observed in all DBP treatment groups. Dead or dying germ cells, primarily consisting of round spermatids, were occasionally seen in the testes of control frogs. However, unlike in the testes of DBP-treated frogs, the number of desquamated spermatids in control testes was very low.

Consequent to germ cell death and wide-spread vacuolization, eventual cell loss at the basal aspect of the tubule was frequently observed in testes from frogs treated with 0.1 ppm DBP and above (Figs. 4C and 4D). Desquamated cellular debris in the lumen and in phagosomes at the basal aspect of Sertoli cells was observed. Although the severity of such lesions increased with increasing concentrations of DBP, lesions were not found in all tubules or in every animal within a treatment group.

In most severe instances of testicular degeneration, all differentiating germ cell nests including spermatogonial nests were lost. This overt degeneration and desquamation of germ cells often resulted in Sertoli cell-only tubules (Fig. 5A) and tubular atrophy with fibrotic changes (Fig. 5B). The atrophic changes in seminiferous tubules were characterized by

TABLE 2
Effects of DBP Exposure During Sexual Differentiation: Spermatogenesis

Treatment	N	Total Number of Seminiferous Tubules Evaluated	Seminiferous Tubules with No Cell Nests (%)	Cell Nests per Seminiferous Tubule (Mean ± SE)	Secondary Spermatogonia[a]	Primary Spermatocytes[a]	Secondary Spermatocytes[a]	Spermatids[a]
FETAX Solution Control	27	2445	0.24	5.6 ± 0.24	7.96	56.44	0.60	35.00
0.01% DMSO Solvent Control	26	2227	0.31	5.3 ± 0.15	6.85	61.39	0.21	31.56
0.1 ppm DBP	28	2356	5.52*	3.2 ± 0.16*	5.72	61.78	0.16	32.73
0.5 ppm DBP	27	2241	7.63*	2.9 ± 0.17*	6.12	62.15	0.32	31.41
1.0 ppm DBP	28	2076	13.54*	2.4 ± 0.19*	4.06*	62.22	0.32	33.40
5.0 ppm DBP	29	2341	14.87*	2.3 ± 0.12*	2.96*	67.32*	0.14	29.58
10.0 ppm DBP	29	2254	18.86*	1.9 ± 0.15*	2.56*	62.68	0.25	34.51

[a]Mean percentage of the total number of cell nests evaluated; 36-100 tubules were evaluated per animal.
*Significantly different ($p < 0.05$) from controls and solvent controls using ANOVA and Tukey/Kramer post-hoc test.

Downloaded from http://toxsci.oxfordjournals.org/ at University of North Texas on January 21, 2017

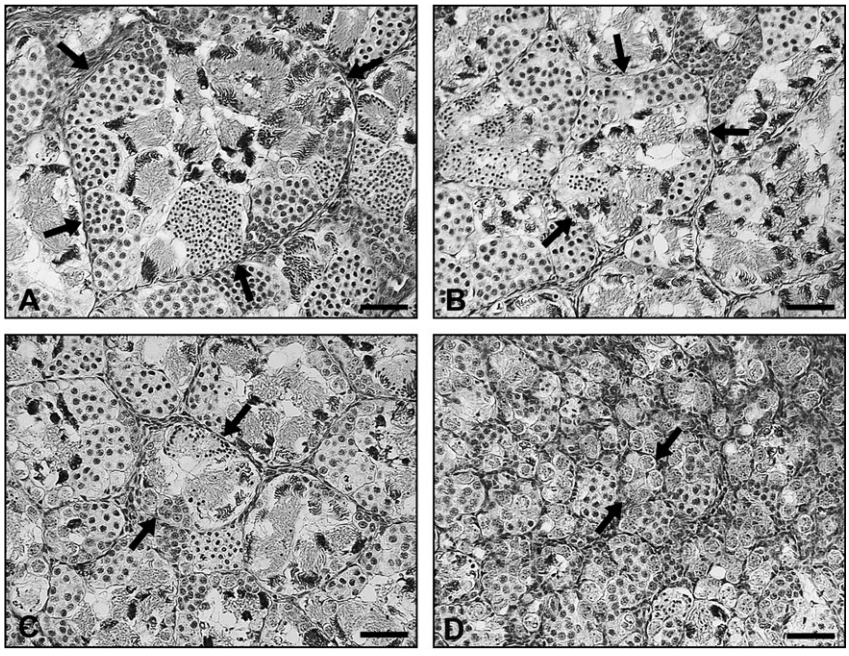

FIG. 3. Testicular histology of *Xenopus laevis*. (A) A typical seminiferous tubule cross section from a solvent control animal. Note the number and variety of cell nests that constitute a normal tubule. Arrows point to the basement membrane that surrounds one tubule. (B–D) Seminiferous tubular profiles of DBP-treated frogs; (B) 0.1 ppm, (C) 1.0 ppm, (D) 10.0 ppm (hypoplastic testis). The number of germ cells in a nest in any stage of spermatogenesis is conspicuously less in all DBP-treated animals. Compare the tubular architecture in DBP-treated frogs with that of the solvent control animal. All images were photographed at the same magnification. Bar = 20 μm.

conspicuous thickening of the lamina propria (Fig. 6). In contrast to germ cell degeneration and tubular atrophy, hypoplastic testes were also found in several animals exposed to 1.0, 5.0, and 10.0 ppm DBP. These hypoplastic testes were characterized by severely regressed seminiferous tubules, but there were no conspicuous changes in the lamina propria (Fig. 3D).

Lymphocytic infiltration was also commonly found in all DBP-treated frogs. The frequency of testes with lymphocytic foci for control, solvent control, 0.1, 0.5, 1.0, 5.0, and 10.0 ppm DBP were 2, 3, 15, 17, 17, 21, and 22%, respectively. Although lymphocytic foci were observed around seminiferous tubules in areas devoid of duct system (Fig. 7A), they were frequently associated with intratesticular rete and efferent ducts (Fig. 7B). A granulomatous lesion occluding testicular efferent duct was observed in one 10.0 ppm DBP-treated frog (Fig. 7C). Inflammatory cells including lymphocytes, mast cells, and histiocytes were found in the granulomatous infiltrate.

Several testes from the 5.0 and 10.0 ppm DBP-treated frogs predominantly contained large areas of seminiferous tubules populated only by mature spermatozoa; a testicular phenotype not observed in control testes (Fig. 8). In some instances, these patches of tubules contained one or two germ cell nests of a different stage, which were often sparsely populated with primary spermatocytes.

Disorganized and misshapen seminiferous tubules were occasionally observed in frogs of all DBP treatment groups, but never observed in any control frogs. These dysgenetic tubules were characterized by maldevelopment and weakening or dissolution of the basement membranes, resulting in loss of a conspicuous tubular profile and disorganization of cell nests (Fig. 9).

Testosterone

Mean testosterone concentrations for control, solvent control, 0.1, 1.0, and 10.0 ppm DBP-treated groups were 0.38, 0.51, 0.25, 0.38, and 0.30 ng/ml, respectively; there was no significant difference between controls and any DBP treatment group. However, there was a trend for reduced testosterone when median values were compared; the median values for control, solvent control, 0.1, 1.0, and 10.0 ppm DBP treatment groups were 0.31, 0.35, 0.17, 0.22, and 0.23 ng testosterone/ml plasma, respectively. Several frogs having both testes had testosterone concentrations <0.1 ng/ml; the incidence was 2, 0, 7, 5, and 5 in the control, solvent control, 0.1, 1.0, and 10.0 ppm DBP treatment groups. All frogs with missing testis (except one in 10 ppm group; 0.05 ng/ml) or retained oviducts had testosterone concentrations >0.1 ng/ml.

DISCUSSION

Exposure to low concentrations of DBP during a short, but critical window of development (i.e., sexual differentiation),

Downloaded from http://toxsci.oxfordjournals.org/ at University of North Texas on January 21, 2017

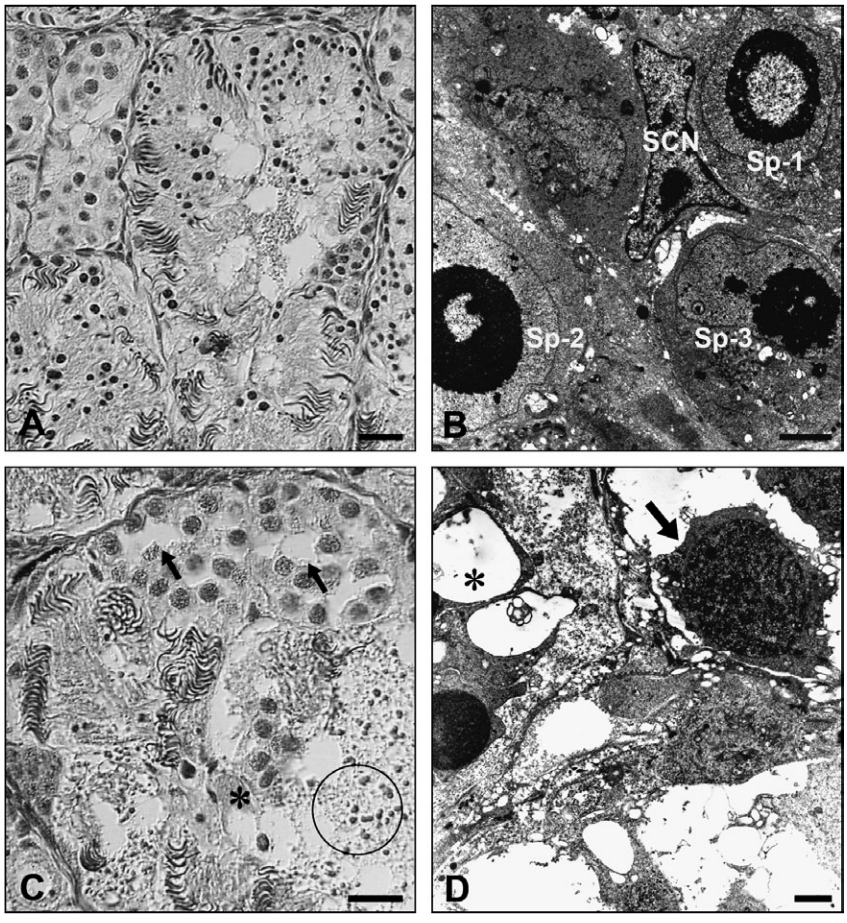

FIG. 4. Germ cell death and vacuolization. (A) Extensive death of round spermatids in seminiferous tubules of a 0.5 ppm DBP-treated frog. (B) An electron micrograph showing the progression of spermatid degeneration in a 5.0 ppm DBP-treated frog. Karyorhectic changes are seen progressively from spermatid 1 (Sp-1) to spermatid 3. (C) Sertoli cell vacuolization at the basal area (arrows) in a pachytene spermatocytic nest in a 0.1 ppm DBP-treated frog. Prematurely exfoliated germ cells (asterisk) and degenerate cellular debris (circle), along with spermatozoa are seen in the lumen. (D) Electron micrograph of the same changes depicted in panel A from a 10.0 ppm DBP-treated frog. Germ cell desquamation (pachytene primary spermatocytes; arrow) in two tubules leaving vacuoles is evident (asterisk). SCN = Sertoli cell nucleus. Bar = 20 μm in A and C; 2 μm in B and D.

impaired development of the male reproductive tract and induced a variety of testicular lesions in *Xenopus laevis* frogs. Most notably, these lesions persisted into adulthood, long after cessation of treatment with DBP.

Missing testis and retained oviducts were present in treated animals at 33 weeks of age. None of the frogs with only one testis had testicular remnants on the contralateral side. Since DBP treatment began after the primitive gonads normally develop in *Xenopus* frogs, and since all control males had both testes, it is likely that DBP interfered with maintenance of testicular integrity. Since several males with testosterone concentrations <0.1 ng/ml had both testes, and all males with missing testis (except one in 10 ppm group) or retained oviducts had testosterone concentrations >0.1 ng/ml, testosterone deficiency cannot be the principal etiological factor underlying these developmental anomalies.

The presence of well-developed oviducts was highest in the 5.0 ppm DBP treatment group and did not occur in any 10.0 ppm DBP-treated males. It is possible that some tadpoles had a genetic predisposition to be more sensitive to DBP, while others were refractory to DBP. This hypothesis is supported by two observations. First, the majority of deaths that contributed to the cumulative mortality rates in DBP treatment groups occurred within the first week of treatment. Second, not all frogs were affected by exposure to DBP, and of those that were adversely affected, a spectrum of lesions, varying in severity, was observed. It is not known if the seemingly developed oviducts would have eventually regressed, since the presence of shortened, regressing paramesonephric ducts is normal around 25 weeks post-metamorphosis in *Xenopus* males (Kelley, 1996). However, the control males had no remnants of regressing ducts. Histological comparisons of the various states of the oviduct in the males compared to females were not possible in this study due to lack of appropriate samples. Regardless, given that *Xenopus laevis* is a strictly gonochoristic species among the genus (Lofts, 1974), and that frogs used in

Downloaded from http://toxsci.oxfordjournals.org/ at University of North Texas on January 21, 2017

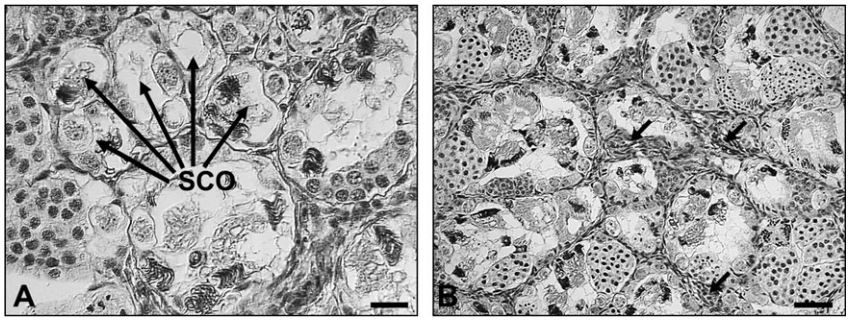

FIG. 5. Progressive degenerative changes. (A) A cluster of Sertoli-cell-only (SCO) tubules in a testis from a 5.0 ppm DBP-treated frog. (B) A testis from a 1.0 ppm DBP-treated frog in which several tubules are atrophic. Notice the thickening of the lamina propria of several tubules and fibrotic changes around ducts in an atrophic tubule (arrows). Bar = 50 μm in A and 20 μm in B.

the current study developed relatively rapidly, presence of well developed oviducts adjacent to testes consisting of seminiferous tubules with mature spermatozoa, is an indication of possible feminization.

Both testis length and width were reduced in DBP-treated frogs. Testis length was significantly reduced in all DBP treatment groups, whereas testis width was reduced only in the 5.0 and 10.0 ppm treatment groups. After sexual differentiation,

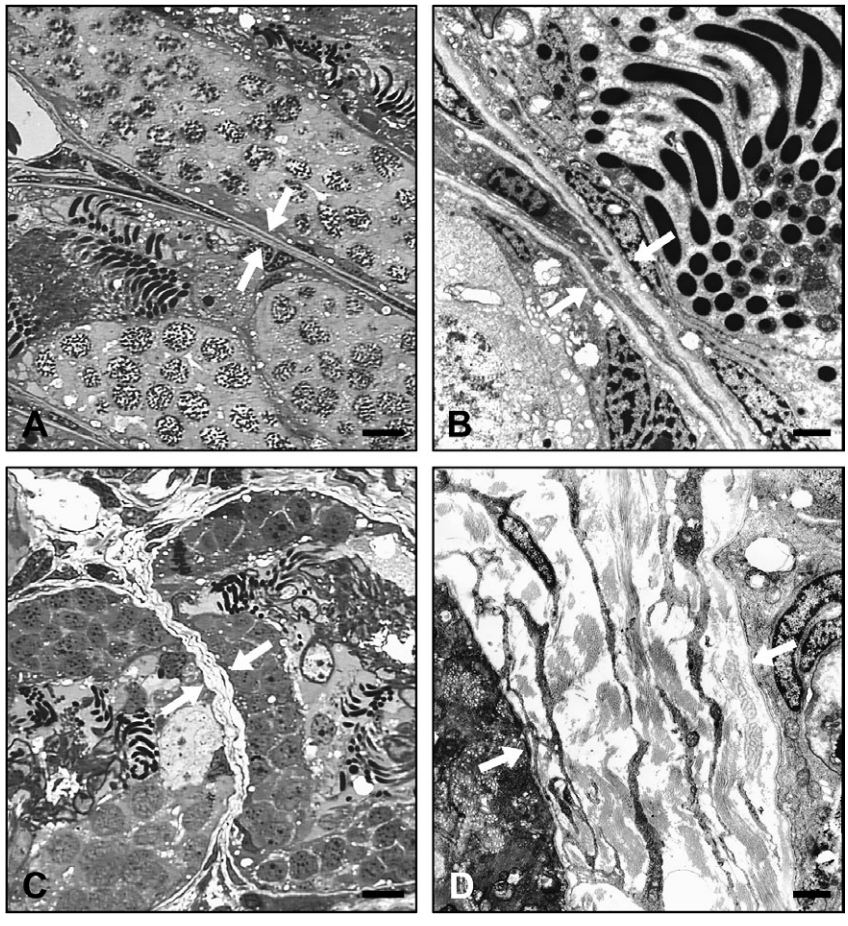

FIG. 6. Thickening of the lamina propria. Semithick and thin sections of seminiferous tubules. (A) The lamina propria (between arrows) in a control frog has smooth contours, a single layer of myoid cells interspersed with very few interstitial cells. (B) An electron micrograph from the same control frog shown in panel A. The lamina propria is tight, containing very few collagen fibers and a myoid cell (MCN). Sertoli cell nuclei (SCN) are seen, and several profiles of condensed spermatozoal heads can be seen in the seminiferous tubule on the right. (C) The thickened lamina propria of a 5.0 ppm DBP-treated frog. The regressed tubules contain darkly stained degenerating spermatocytes. The basement membrane of both tubules looks wavy and contorted. (D) An electron micrograph from the same 5.0 ppm DBP-treated male is shown in panel C. Here the thickening of the lamina propria is obvious, with several layers of collagen fibers (arrows). Bar = 10 μm in A and C; 2 μm in B and D.

Downloaded from http://toxsci.oxfordjournals.org/ at University of North Texas on January 21, 2017

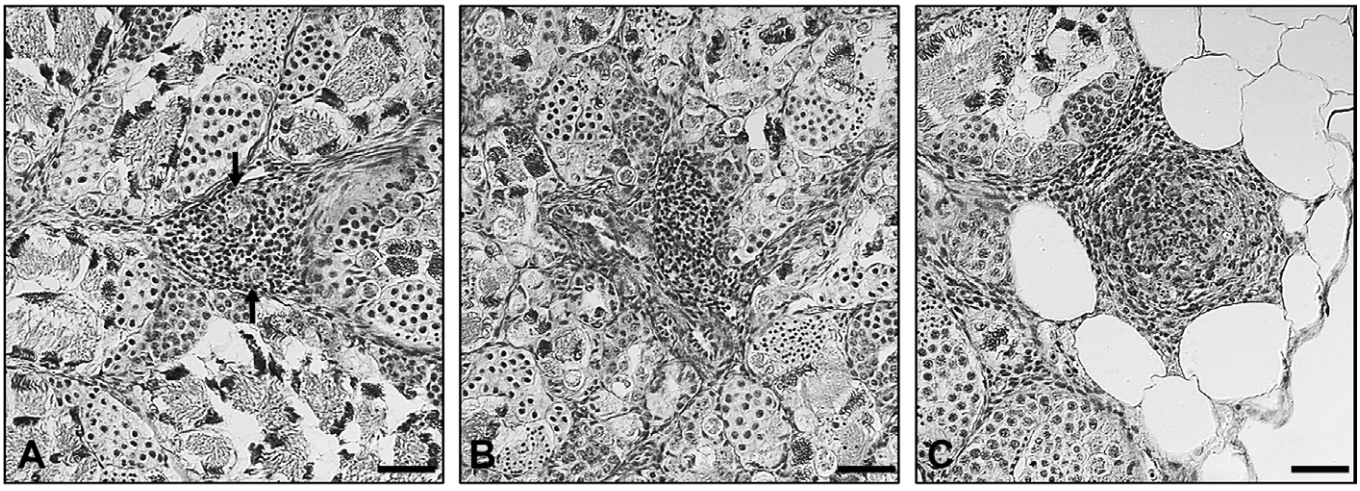

FIG. 7. Focal lymphocytic infiltration. (A) Testis of a 0.5 ppm DBP-treated frog in which lymphocytes have infiltrated a seminiferous tubule in a degenerate area. Several small Sertoli cell phagosomes (arrows) can be seen among the lymphocytes. (B) Lymphocytic infiltration into the rete testis from a 1.0 ppm DBP-treated frog. (C) A completely occluded extratesticular efferent duct of a 10.0 ppm DBP-treated frog that has undergone a granulomatous reaction. Bar = 50 μm.

the testis grows in length much more than in width (Kelley, 1996). Therefore, the testis growth as reflected by the length could be primarily affected by DBP. Given that testicular atrophy was much more common in the 5.0 and 10.0 ppm DBP-treated frogs, testicular width, which was also significantly reduced at these concentrations, may be a sensitive endpoint to evaluate DBP-induced testicular atrophy. The usefulness of morphometric measurements to evaluate normal testicular function is further evident by the lack of sensitivity of the relative testis-kidney weights at concentrations lower than 10.0 ppm DBP. Other studies have also found that testis weight alone is not an adequate measurement to assess the reproductive status in frogs with a continuous spermatogenic cycle, such as *Xenopus* (discussed in Sasso-Cerri *et al.*, 2004).

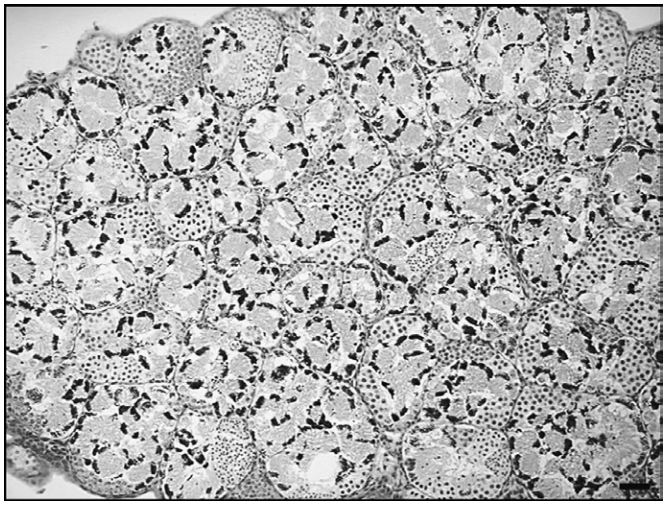

FIG. 8. Seminiferous tubules with retained sperm. Several tubules containing mature spermatozoa from a 10.0 ppm DBP-treated frog. Tubules are predominantly populated by nests of spermatozoa, with occasional nests containing primary spermatocytes. Bar = 50 μm.

Seminiferous tubular diameter was significantly reduced in all DBP treatment groups, along with a decrease in the average number of cell nests per tubule. Tubule diameter is correlated with the number of cell nests supported within a seminiferous tubule ($R^2 = 0.865$; $p < 0.01$). In general, morphological and histological alterations in the testes of DBP-treated frogs closely correlated with reduction in tubule diameter and the average number of cell nests per tubule.

The percent of secondary spermatogonial nests was significantly decreased in frogs treated with 1.0 ppm DBP and above. Although it has been shown that spermatogonia are the least likely to be affected by exposure to toxicants (reviewed by Boekelheide, 1993), DBP might be an exception. Other than an increase in the percentage of primary spermatocytes in the 5.0 ppm DBP-treated frogs, there was no change in the percentage of secondary spermatocytic or spermatidal germ cell nests. The isolated increase in the primary spermatocytes only in the 5.0 ppm treatment group cannot be explained. However, this may indicate that DBP retarded the progression of pachytene primary spermatocytes in some animals at this concentration. It is likely that a reduced cohort of spermatogonia entering the spermatogenic cycle would result in a lower number of spermatozoa produced by the testis which, in turn, would reduce the reproductive capability of the frog. This could be particularly detrimental to species that rely on a large quantity of sperm that is required for successful external fertilization.

Vacuolization of Sertoli cell cytoplasm was frequently observed in animals treated with 0.1 ppm DBP and above. It is important to note that spermiating cell nests are often highly vacuolated at the apical portions of the Sertoli cell cytoplasm, as the cells will retain fluid to loosen the cell–cell associations prior to releasing the spermatozoa (Burgos *et al.*,

Downloaded from http://toxsci.oxfordjournals.org/ at University of North Texas on January 21, 2017

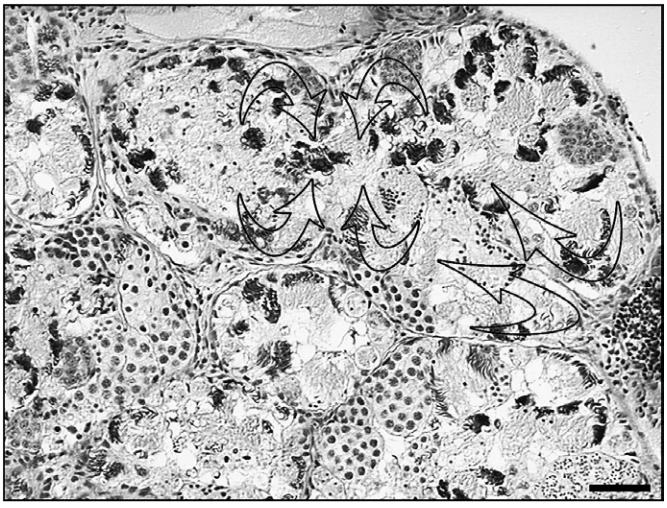

FIG. 9. Dysgenetic seminiferous tubules. Three dysgenetic seminiferous tubules from a 0.1 ppm DBP-treated frog. Tubular structure and cell nest associations are disorganized. A cluster of lymphocytes can be seen on the right edge. Arrows delineate the basement membrane of each tubule and the direction in which each should have developed normally. Bar = 50 μm.

1967). However, vacuolization at the basal area is not normal, especially during early stages of spermatogenesis. Furthermore, vacuolization of the Sertoli cell cytoplasm is a common lesion produced by a number of xenobiotics and is one of the earliest morphological indications of testicular injury (Boekelheide, 1993). As a result of extensive vacuolization with the eventual retraction or degeneration of ectoplasmic specializations, individual or entire cohorts of germ cells were seen denuded in the lumen of tubules of DBP-treated frogs. Gray and Beamand (1984) observed this phenomenon in Sertoli-germ cell cocultures treated with phthalates. Vacuolization of Sertoli cells may have resulted from death and denudation of differentiating germ cells. This was evident in electron microscopic evaluations, which revealed disrupted spermatids with necrotic as well as apoptotic changes in spermatids and spermatocytes and eventual desquamation.

Thickening of the lamina propria seen in DBP-treated frogs was most severe in the 5.0 and 10.0 ppm groups. Normally, the interstitial spaces between seminiferous tubules primarily populated with spermatocytic germ cell nests are meager, and the lamina propria is tightly juxtaposed with the tubule (Pudney and Callard, 1984). Although interactions between seminiferous tubules, myoid, and interstitial cells have been established in mammals (Tripp and Lamb, 1997), such mechanisms are not understood in amphibians. However, increased interstitial volume usually accompanies the regression of seminiferous tubules in anurans (Sasso-Cerri *et al.*, 2004). It has been suggested that damage to existing basal lamina or synthesis of its components may result in the solubilization of basal lamina, which, in turn, may lead to an autoimmune type of reaction and consequent thickening (Kefalides, 1975). Similar abnormalities in basal lamina and components of the lamina propria have been observed in men (de Kretser *et al.*, 1975) and bulls (Veeramachaneni *et al.*, 1987) with seminiferous tubular failure and deranged spermatogenesis. DBP may have produced such reactions in frog testes.

Lymphocytic infiltration was a very common lesion found in testes of DBP-treated animals and increased in a dose-dependent manner. Creasy *et al.* (1983) observed an acute inflammatory cell infiltration in testes of sexually immature rats exposed to 2.2 g/kg di-*n*-pentyl phthalate, which diminished within a day. In contrast, lymphocytic infiltration observed in DBP-treated frogs persisted 25 weeks after the cessation of treatment. It is known that loss of integrity of the basement membrane results in chemotaxis. Since the basement membrane components are secreted in part by the Sertoli cells (Hadley *et al.*, 1985), and DBP is a known Sertoli cell toxicant (Boekelheide, 1993), it is possible that the basement membrane integrity in the DBP-treated frogs was compromised, resulting in chronic lymphocytic infiltration.

The complete disorganization of seminiferous tubular architecture observed in some DBP-treated frogs is similar to the branching described in rats treated with high doses of DBP (Fisher *et al.*, 2003). However, this form of testicular dysgenesis has never been described at such low concentrations of DBP. Skakkebaek *et al.* (2001) described a testicular dysgenesis syndrome encompassing a variety of pathological disorders of the male reproductive tract in humans, including poor semen quality, testicular cancer, undescended testis, and hypospadias. Disorganization of seminiferous tubules and poor differentiation of the germinal epithelium are hallmarks of testicular dysgenesis. DBP, even at low concentrations, may have produced similar effects in frogs.

A very unique seminiferous tubular phenotype—populated only with elongated spermatozoa—was observed in DBP-treated frogs. Such a tubular profile with retained spermatozoa would be expected in winter in several species of urodeles in which spermatogenesis is discontinuous (Pudney, 1995). However, spermatogenesis in *Xenopus* frogs is continuous. Retained spermatozoa can also be observed in amphibians exhibiting cystic spermatogenesis under natural conditions during the ''spawning'' period (Lofts, 1968). Before this event, large numbers of spermatozoa are accumulated in the tubules (Lofts, 1968). However, the ''spawning'' period is not likely to occur in frogs under constant laboratory conditions; normally the natural breeding season of *Xenopus* living in their native habitat occurs immediately following the monsoon. There are no studies that report this particular phenotype in frogs maintained under laboratory conditions. It is important to note that only DBP-treated frogs, and not controls, had such a testicular histological phenotype, which indicates that DBP may have impaired spermiation. Since spermiation is a testosterone-dependent process in amphibians (Rastogi, 1976), it is possible that intratesticular testosterone concentrations were

Downloaded from http://toxsci.oxfordjournals.org/ at University of North Texas on January 21, 2017

insufficient. However, in light of the spectrum of other degenerative changes observed in DBP-treated testes, it is also plausible that retained sperm is a result of damage to the Sertoli cells. Sperm retention has also been observed in rats treated with water disinfection by-products such as dibromoacetic acid (Linder *et al.*, 1994, 1997).

Although the mean concentration of plasma testosterone in DBP treatment groups was not significantly different from that of controls, the median value in all DBP treatment groups was less than that of controls. Several animals treated with DBP had low testosterone concentrations. Twenty-nine, 30, and 23 animals in the 0.1, 1.0, and 10.0 ppm groups had testosterone concentrations less than control and solvent control median values (0.31; 0.35). The fact that testosterone concentrations in several frogs treated with DBP were low even 25 weeks after dosing indicates that the effects of DBP are not transient in all animals within a given population, and it is quite possible that widespread, testosterone insufficiency was prevalent during dosing and immediately thereafter, as seen in many mammalian studies that tested DBP or di-ethylhexyl phthalate (Fisher *et al.*, 2003, Mylchreest *et al.*, 2002; Parks *et al.*, 2000).

The qualitative histological observations from this study indicate that DBP, at 0.1 ppm and above, causes the same spectrum of testicular lesions in *Xenopus* as seen in mammals exposed to high doses of DBP and other phthalates (di-ethylhexyl phthalate and di-*n*-pentyl phthalate). The nature of predominant histological lesions in the seminiferous epithelium, viz., progressive degenerative changes, indicate that the lesions are most likely caused by a direct insult to the Sertoli cells and/or germ cells and not an indirect consequence of general growth retardation.

Although the lowest concentration of DBP used in this study, 0.1 ppm, is higher than average concentrations found in some water sources (A.T.S.D.R., 2001), concentrations higher than 0.1 ppm also have been found in air (0.01–6.18 $\mu g/m^3$ (ppm), Otake *et al.*, 2004) and soil (73–210 ppb, Malisch *et al.*, 1981). More importantly, the concentration of MBP detected in human matrices is often higher than 0.1 ppm (Blount *et al.*, 2000). Thus it is very likely that some populations are exposed to high enough concentrations of DBP similar to the ones used in this study. Collectively, the data from the current study are the first to show that environmentally relevant concentrations of DBP, as low as 0.1 ppm, have the potential to be detrimental damage to populations of amphibians by affecting spermatogenesis.

Unlike the current study using *Xenopus laevis,* toxicological studies using a mammalian model to study the effects of DBP, at relatively low doses, were unable to detect subtle changes in the testis. Thus, *Xenopus laevis* is perhaps a good model to study the low-dose effects of DBP on early development and sexual differentiation. As has been demonstrated in earlier studies (e.g., Mylchreest *et al.*, 1999, 2000), the ability to study or monitor a large number of animals is crucial to our understanding of how environmental EDCs such as phthalates adversely affect a small fraction of individuals within a population. It is critical that samples of any physiological matrix from different animals are not pooled and subsequently used to arrive at a scientific conclusion concerning the effects of DBP. In this context, use of *Xenopus laevis* facilitates studies necessitating large sample sizes because of relatively lower costs. Furthermore, ongoing studies in our laboratory (Owens, unpublished) indicate *Xenopus laevis* embryos metabolize DBP to MBP akin to mammalian systems, making *Xenopus laevis* a useful animal model.

The adverse effects of low doses of DBP in the current study may have been enhanced by chronic dermal exposure as a result of living in an aquatic environment. In mammals, *in utero* exposure to DBP often results in the most detrimental effects (Gray *et al.*, 1999, 2001; Higuchi *et al.*, 2003; Mylchreest *et al.*, 1999, 2000, 2002). Since MBP has been shown to cross the placental barrier and be present in amniotic fluid following a single dose of DBP (Saillenfait *et al.*, 1998), it is possible that low concentrations, like those tested herein, would be present in amniotic fluid subsequent to chronic maternal exposures. Thus chronic, low-dose, transcutaneous exposure of amphibians may mimic/model similar exposure of mammals in amniotic fluid. Dermal route of exposure to DBP has been considered much more significant than once thought (Blount *et al.*, 2000).

Although DBP does not extensively bioaccumulate in most environmental strata, it is continuously being released into the environment, where it may act synergistically or additively with many other contaminants, leading to significant changes in behavior, physiology, and eventually population dynamics in all organisms. For decades DBP has been a ubiquitous pollutant and is only now being realized as one of many components of an enormous ecological problem that is poorly understood. In summary, these data show that low concentrations of DBP disrupts spermatogenesis in *Xenopus laevis* by inducing a variety of testicular lesions, with varying degrees of severity.

ACKNOWLEDGMENTS

We thank Gwen Owens, Jennifer Palmer, Ginger Sammonds, and Carol Moeller for technical assistance. This research was supported by the U.S. EPA STAR grant R829429.

REFERENCES

A.T.S.D.R. (2001). *Toxicological Profile for Di-n-Butyl Phthalate.* Agency for Toxic Substances and Disease Registry. Atlanta, GA.

Adams, W. J., Biddinger, G. R., and Robillard, K. A. (1995). A summary of the acute toxicity of 14 phthalate esters to representative aquatic organisms. *Environ. Toxicol. Chem.* **14,** 1569–1574.

Adibi, J. J., Perera, F. P., Jedrychowski, W., Camann, D. E., Barr, D., Jacek, R., and Whyatt, R. M. (2003). Prenatal exposures to phthalates among women

Downloaded from http://toxsci.oxfordjournals.org/ at University of North Texas on January 21, 2017

in New York City and Krakow, Poland. *Environ. Health Perspect.* **111,** 1719–1722.

American Society for Testing and Materials (A.S.T.M). (1998) Standard guide for conducting the frog embryo teratogenesis assay-Xenopus (FETAX). In *Annual Book of ASTM Standards.* vol. 11.01, pp. 790–804, ASTM, Philadelphia, PA.

Blaustein, A. R., and Kiesecker, J. M. (2002). Complexity in conservation: Lessons from the global decline of amphibian populations. *Ecol. Lett.* **5,** 597–608.

Blount, B. C., Silva, M. J., Caudill, S. P., Needham, L. L., Pirkle, J. L., Sampson, E. J., Lucier, G. W., Jackson, R. J., and Brock, J. W. (2000). Levels of seven urinary phthalate metabolites in a human reference population. *Environ. Health Perspect.* **108,** 972–982.

Boekelheide, K. (1993). Sertoli cell toxicant. In *The Sertoli Cell* (L. D. Russell and M. D. Griswold, Eds.), 1st ed., pp. 551–575. Cache River Press, Clearwater, FL.

Brandt, K. (1985). Final report on the safety assessment of dibutyl phthalate, dimethyl phthalate, and diethyl phthalate. *J. Am. Coll. Toxicol.* **4,** 267–303.

Burgos, M. H., and Vitale-Calpe, R. (1967). The fine structure of the Sertoli cell-spermatozoan relationship in the toad. *J. Ultrastruc. Res.* **19,** 221–237.

Burkhart, J. G., Helgen, J. C., Fort, D. J., Gallagher, K., Bowers, D., Propst, T. L., Gernes, M., Magner, J., Shelby, M. D., and Lucier, G. (1998). Induction of mortality and malformations in *Xenopus laevis* embryos by water sources associated with field frog deformities. *Environ. Health Perspect.* **106,** 841–848.

Creasy, D. M., Foster, J. R., and Foster, P. M. D. (1983). The morphological development of di-n-pentyl phthalate induced testicular atrophy in the rat. *J. Pathol.* **139,** 309–321.

de Kretser, D. M., Kerr, J. B., and Paulsen, C. A. (1975). The peritubular tissue in the normal and pathological human testis. An ultrastructural study. *Biol. Reprod.* **12,** 317–324.

Ema, M., Amano, H., and Ogawa, Y. (1994). Characterization of the developmental toxicity of di-n-butyl phthalate in rats. *Toxicology* **86,** 163–174.

Fisher, J. S., Macpherson, S., Marchetti, N., and Sharpe, R. M. (2003). Human testicular dysgenesis syndrome: A possible model using in-utero exposure of the rat to dibutyl phthalate. *Human Reprod.* **18,** 1383–1394.

Gray, L. E., Jr., Ostby, J., Furr, J., Wolf, C. J., Lambright, C., Parks, L., Veeramachaneni, D. N., Wilson, V., Price, M., Hotchkiss., A., *et al.* (2001). Effects of environmental antiandrogens on reproductive development in experimental animals. *Human Reprod. Update* **7,** 248–264.

Gray, L. E., Jr., Wolf, C., Lambright, C., Mann, P., Price, M., Cooper, R. L., and Ostby, J. (1999). Administration of potentially antiandrogenic pesticides (procymidone, linuron, iprodione, chlozolinate, p,p′-DDE, and ketoconazole) and toxic substances (dibutyl- and diethyl phthalate, PCB 169, and ethane dimethane sulphonate) during sexual differentiation produces diverse profiles of reproductive malformations in the male rat. *Toxicol. Ind. Health* **15,** 94–118.

Gray, T. J. B., and Beamand, J. A. (1984). Effect of some phthalate esters and other testicular toxins on primary cultures of testicular cells. *Food Chem. Toxicol.* **22,** 123–131.

Hadley, M. A., Byers, S. W., Suarez-Quian, C. A., Kleinman, H. K., and Dym, M. (1985). Extracellular matrix regulates Sertoli cell differentiation, testicular cord formation, and germ cell development *in vitro*. *J. Cell Biol.* **101,** 1511–1522.

Hayes, T., Haston, K., Tsui, M., Hoang, A., Haeffele, C., and Vonk, A. (2003). Atrazine-induced hermaphroditism at 0.1 ppb in American leopard frogs (*Rana pipiens*): Laboratory and field evidence. *Environ. Health Perspect.* **111,** 568–575.

Higuchi, T. T., Palmer, J. S., Gray, L. E., Jr., and Veeramachaneni, D. N. R. (2003). Effects of dibutyl phthalate in male rabbits following *in utero,* adolescent, or postpubertal exposure. *Toxicol. Sci.* **72,** 301–313.

Higuchi, T., weber, N., Veeramachaneni, D. N. R. (2000). Characterization of developmental toxicity of di-n-butyl phthalate using the frog embryo teratogenisis assay-Xenopus (FETAX). *Biol. Reprod.* **62,** Suppl 1: abstract 352.

Houlahan, J. E., Findlay, C. S., Schmidt, B. R., Meyer, A. H., and Kuzmin, S. L. (2000). Quantitative evidence for global amphibian declines. *Nature* **404,** 752–755.

Kalt, M. R. (1976) Morphology and kinetics of spermatogenesis in *Xenopus laevis*. *J. Exp. Zool.* **195,** 393–408.

Kang, L., Marin, M., and Kelley, D. (1995) Androgen biosynthesis and secretion in developing *Xenopus laevis*. *Gen. Comp. Endocrinol.* **100,** 293–307.

Kefalides N. A. (1975). Basement membranes: Current concepts of structure and synthesis. *Dermatologica* **150,** 4–15.

Kelley, D. B. (1996). Sexual differentiation in *Xenopus*. In *Biology of Xenopus* (R. C. Tinsley and H. R. Kobel, Eds.), pp. 143–176. Clarendon Press, Oxford.

Kloas, W., Lutz, I., Einspainier, R. (1999). Amphibians as a model to study endocrine disruptors: II. Estrogen activity of environmental chemicals *in vitro* and *in vivo*. *Sci Total environ.* **225,** 59–68.

Kluwe, W. M. (1982). Overview of phthalate ester pharmacokinetics in mammalian species. *Environ. Health Perspect.* **45,** 3–10.

Laczko, L., and Levai, G. (1975). A simple differential staining method for semi-thin sections of ossifying cartilage and bone tissues embedded in epoxy resin. *Mikroskopie* **31,** 1–4.

Lee, S. K., Owens, G. A., and Veeramachaneni, D. N. R. (2005). Exposure to low concentrations of di-*n*-butyl phthalate during embryogenesis reduces survivability and impairs development of *Xenopus laevis* frogs. *J. Toxicol. Environ. Health Part A* (in press).

Levy, G., Lutz, I., Kruger, A., and Kloas, W. (2004). Bisphenol A induces feminization in *Xenopus laevis* tadpoles. *Environ. Res.* **94,** 102–111.

Linder, R. E., Klinefelter, G. R., Strader, L. F., Suarez, J. D., Roberts, N. L., and Dyer, C. J. (1994). Spermatotoxicity of dibromoacetic acid in rats after 14 daily exposures. *Reprod. Toxicol.* **8,** 251–259.

Linder, R. E., Klinefelter, G. R., Strader, L. F., Veeramachaneni, D. N. R., Roberts, N. L., and Suarez, J. D. (1997). Histopathologic changes in the testes of rats exposed to dibromoacetic acid. *Reprod. Toxicol.* **11,** 47–56.

Lofts, B. (1968). Patterns of testicular activity. In *Perspectives in Endocrinology: Hormones in the Liver of Lower Vertebrates* (E. W. J. Barrington and C. B. Jorgensen, Eds.), pp. 239–306. Academic Press, New York.

Lofts, B. (1974). Reproduction. In *Physiology of the Amphibia.* (B. Lofts, Ed.) pp. 107–200. Academic Press, New York.

Malisch, V. R., Schutte, E., and Acker, L. (1981). Choro-organic pesticides, polychlorinated biphenyls, and phthalates in sediment from the Rhein River. *Chemiker Zeitung* **105,** 187–194.

Mylchreest, E., Sar, M., Cattley, R. C., and Foster, P. M. D. (1999). Disruption of androgen-regulated male reproductive development by di(n-butyl) phthalate during gestation in rats is different from flutamide. *Toxicol. Appl. Pharmacol.* **156,** 81–95.

Mylchreest, E., Sar, M., Wallace, D. G., and Foster, P. M. D. (2002). Fetal testosterone insufficiency and abnormal proliferation of Leydig cells and gonocytes in rats exposed to di(n-butyl) phthalate. *Reprod. Toxicol.* **16,** 19–28.

Mylchreest, E., Wallace, D. G., Cattley, R. C., and Foster, P. M. D. (2000). Dose-dependent alterations in androgen-regulated male reproductive development in rats exposed to di(n-butyl) phthalate during late gestation. *Toxicol. Sci.* **55,** 143–151.

Downloaded from http://toxsci.oxfordjournals.org/ at University of North Texas on January 21, 2017

Nieukoop, P. D. and Faber, J., eds (1967). *Normal Table of Xenopus laevis (Daudin): A systematic and chronological survey of the development from the fertilized egg until the end of metamorphosis.* North Holland Publishing, Amsterdam.

Ohtani, H., Miura, I., and Ichikawa, Y. (2000). Effects of dibutyl phthalate as and environmental endocrine disruptor on gonadal sex differentiation of genetic males of the frog *Rana rugosa*. *Environ. Health Perspect.* **108,** 1189–1193.

Otake, T., Yoshinaga, J., and Yanagisawa, Y. (2004). Exposure to phthalate esters from indoor environment. *J. Expo. Anal. Environ. Epidemiol.* **14,** 524–528.

Parks, L. G., Ostby, J. S., Lambright, C. R., Abbott, B. D., Klinefelter, G. R., Barlow, N. J., and Gray, L. E., Jr. (2000). The plasticizer diethylhexyl phthalate induces malformations by decreasing fetal testosterone synthesis during sexual differentiation in the male rat. *Toxicol. Sci.* **58,** 339–349.

Petersen, J. H., and Breindahl, T. (2000). Plasticizers in total diet samples, baby food and infant formulae. *Food Add. Contam.* **17,** 133–141.

Peterson, J. C., and Freeman, D. H. (1982). Phthalate ester concentration variations in dated sediment cores from the Chesapeake Bay. *Environ. Sci. Technol.* **16,** 464–469.

Pudney, J. (1995). Spermatogenesis in non-mammalian vertebrates. *Microsc. Res. Tech.* **32,** 459–497.

Pudney, J., and Callard, G. V. (1984). Organization of interstitial tissue in the testis of the salamander Necturus maculosus. *J. Morphol.* **181,** 87–95.

Rastogi, R. K. (1976). Seasonal cycle in anuran (amphibia) testis: The endocrine and environmental controls. *Bull. Zool.* **43,** 151–172.

Rozati, R., Reddy, P. P., Reddanna, P., and Mujtaba, R. (2002). Role of environmental estrogens in the deterioration of male factor fertility. *Fertil. Steril.* **78,** 1187–1194.

Saillenfait, A. M., Payan, J. P., Fabry, J. P., Beydon, D., Langonne, I., Gallissot, F., and Sabate, J. P. (1998). Assessment of the developmental toxicity, metabolism, and placental transfer of di-n-butyl phthalate administered to pregnant rats. *Toxicol. Sci.* **45,** 212–224.

Sasso-Cerri, E., De Faria, F. P., Freymuller, E., and Miraglia, S. M. (2004). Testicular morphological changes during the seasonal reproductive cycle in the bullfrog *Rana catesbeiana*. *J. Exp. Zool.* **301A,** 249–260.

Skakkebaek, N. E., Rajpert-DeMeyts, E. R., and Main K. M. (2001). Testicular dygenesis syndrome: An increasingly common developmental disorder with environmental aspects. *Human Reprod.* **16,** 972–978.

Stuart, S. N., Chanson, J. S., Cox, N. A., Young B. E., Rodrigues, A. S. L., Fischman, D. L., and Waller, R. W. (2004). Status and trends of amphibian declines and extinctions worldwide. *Science* **306,** 1783–1786.

Tripp, B. M., and Lamb, D. J. (1997). Sertoli cell: Morphology, function, and regulation. In *Infertility in the Male* (L. I. Lipshultz, and S. S. Howards Eds.), 1st ed., pp. 71–105. Mosby, Saint Louis, MO.

U.S. EPA (2004). EPA Fact Sheet: National Listing of Fish Advisories. United States Environmental Protection Agency, http://www.epa.gov/waterscience/fish/.

Veeramachaneni, D. N. R., Heath, E. H., Ott, R. S., McEntee, K., and Hixon, J. E. (1987). Changes in the basal lamina of seminiferous tubules associated with deranged spermatogenesis in the bull. *Am. J. Vet. Res.* **48,** 243–245.

Weber, N., Higuchi, T., Tessari, J., and Veeramachaneni, D. N. R. (2004). Evaluation of the effects of water disinfection by-products, bromochloroacetic acid and dibromoacetic acids, on frog embryogenesis. *J. Toxicol. Environ. Health, Part A.* **67,** 929–939.

Downloaded from http://toxsci.oxfordjournals.org/ at University of North Texas on January 21, 2017